






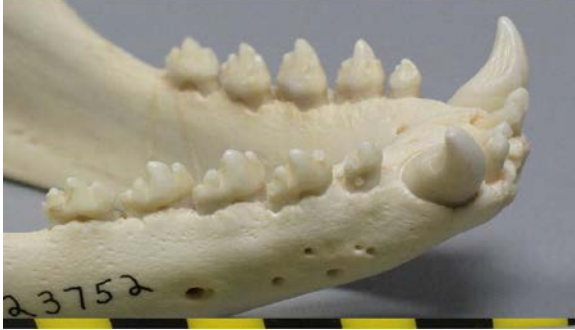












California Sea Lion (CSLI)	Harbor Seal (HASE)	Northern Elephant Seal (NESE)
 <p>Skull: Strong sexual dimorphism; triangular postorbital processes; wide intraorbital region; adult male has pronounced sagittal crest</p>	 <p>Skull: Minimal sexual dimorphism; no postorbital processes; narrow intraorbital region; large auditory bullae (on ventral side, not shown in photo)</p>	 <p>Skull: Strong sexual dimorphism; no postorbital processes, large nasal shelf</p>
 <p>Scapula: Large with two ridges</p>	 <p>Scapula: Comma-shaped with a single ridge</p>	 <p>Scapula: Large, fan-shaped with a single ridge</p>
 <p>Teeth: Unicuspid post canines with strong cingulum often bearing accessory cusplets; upper postcanines generally uniformly spaced; third upper incisor enlarged</p>	 <p>Teeth: Postcanine teeth usually bearing at least 3 cusps (mountainous); upper incisors of uniform size</p>	 <p>Teeth: Very large canines, postcanines reduced and peglike, lacking cusps; total of 2 lower incisors</p>

Steller Sea Lion (SSLI)	Northern Fur Seal (NOFS)	Guadalupe Fur Seal (GUFS)
 <p>Skull: Strong sexual dimorphism; adult male has no obvious sagittal crest; square or rectangular postorbital processes; wide intraorbital region</p>	 <p>Skull: Obvious sexual dimorphism; postorbital processes point back; greatest width across nasals almost equaling their length (snout short)</p>	 <p>Skull: Strong sexual dimorphism (no male pictured); postorbital processes point outwards; greatest width across nasals about one-half their length (snout long)</p>
 <p>Scapula: Very large with two ridges</p>	 <p>Scapula: Small with two ridges</p>	 <p>Guadalupe Fur Seal ♀ Northern Fur Seal ♀</p>
 <p>Teeth: Large canines; unicuspid postcanines, no cusplets; wide gap separating last upper postcanine from its predecessor in adults; third upper incisor enlarged</p>	 <p>Teeth: Large canines; unicuspid postcanines with possible minor cusplets; third upper incisor enlarged</p>	 <p>Guadalupe Fur Seal ♀ N. Fur Seal ♀</p>